

2. Elias JM: 1997, Cell proliferation indexes: a biomarker in solid tumors. *Biotechnol Histochem* 72:78–85.
3. Healey JH, Lane JM: 1989, Chordoma: a critical review of diagnosis and treatment. *Orthop Clin N Am* 20:417–426.
4. Kiupel M, Teske E, Bostock D: 1999, Prognostic factors for treated canine malignant lymphoma. *Vet Pathol* 36:292–300.
5. Leong AS, Wick MR, Swanson PE: 1997, The anaplastic round cell tumor. *In: Immunohistology and electron microscopy of anaplastic and pleomorphic tumors*, pp. 109–209. Cambridge University Press, Cambridge, UK.
6. Ploton D, Menager M, Jeannesson P, et al.: 1986, Improvement in the staining and in the visualization of the argyrophilic proteins of the nucleolar organizer region at the optical level. *Histochem J* 18:5–14.
7. Pye GW, Bennett RA, Roberts GD, Terrell SP: 2000, Thoracic vertebral chordoma in a domestic ferret (*Mustela putorius furo*). *J Zoo Wildl Med* 31:107–111.
8. Rich TA, Schiller A, Suit HD, Mankin HJ: 1985, Clinical and pathologic review of 48 cases of chordoma. *Cancer* 56:182–187.
9. Su WP, Louback JB, Gagne EJ, Scheithauer BW: 1993, Chordoma cutis: a report of nineteen patients with cutaneous involvement of chordoma. *J Am Acad Dermatol* 29:63–66.
10. Volpe R, Mazabraud A: 1983, A clinicopathologic review of 25 cases of chordoma (a pleomorphic and metastasizing neoplasm). *Am J Surg Pathol* 7:161–170.
11. Williams BH, Eighmy JJ, Berbert MH, Dunn DG: 1993, Cervical chordoma in two ferrets (*Mustela putorius furo*). *Vet Pathol* 30:204–206.
12. Winer BJ: 1971, *Statistical principles of experimental design*. McGraw Hill, New York, NY.

*J Vet Diagn Invest* 16:458–460 (2004)

## Molecular epidemiology of two fowl cholera outbreaks on a free-range chicken layer farm

P. Zhang<sup>1</sup>, N. Fegan, I. Fraser, P. Duffy, R. E. Bowles, A. Gordon, P. J. Ketterer, W. Shinwari, P. J. Blackall

**Abstract.** Two outbreaks of fowl cholera on a multiage free-range egg farm were investigated. The outbreaks occurred in 1994 and 2002. A total of 22 strains of *Pasteurella multocida* were available for study, 11 from the 1994 outbreak and 11 from the 2002 outbreak. Lesions typical of acute fowl cholera were seen in the 1994 outbreak, whereas both acute and chronic fowl cholera occurred in the 2002 outbreak. The isolates were examined in an extended phenotypic typing methodology, by a *P. multocida*-specific polymerase chain reaction (PCR), by the Heddleston somatic serotyping scheme, and by restriction endonuclease analysis (REA) typing using the enzyme *HpaII*. All 22 strains had the same phenotypic properties, all were confirmed as *P. multocida* by PCR, all were Heddleston serovar 4, and all had the same REA pattern. The results indicate that these 2 outbreaks were caused by the same clone of *P. multocida*—despite the 8-year time period between the outbreaks.

Fowl cholera is a common and widely distributed disease of poultry and is of major economic importance.<sup>16</sup> The disease is caused by the bacterium *Pasteurella multocida*.<sup>16</sup> Three subspecies within *P. multocida* (*P. multocida* subsp. *multocida*, *P. multocida* subsp. *septica*, and *P. multocida* subsp. *gallicida*) are now recognized.<sup>15</sup> Molecular techniques such as restriction endonuclease analysis (REA) and ribotyping have enabled researchers to distinguish clones of *P. multocida* as a method of studying outbreaks of fowl cholera in turkeys.<sup>1,2,4,5,11</sup> However, there are only lim-

ited reports of the use of these techniques for fowl cholera outbreaks associated with chickens.<sup>3,13,14</sup>

In this report, the use of REA and conventional biochemical and serological typing to examine the molecular epidemiology of 2 acute outbreaks of fowl cholera, separated by 8 years, on a free-range layer farm is described.

The 2 outbreaks occurred on a free-range egg farm located near the coast of Central Queensland, Australia. In 1994, the farm had 5 sheds housing a total of 8,000 chickens. By 2002, there were 15 sheds and a total of 50,000 layers. The birds were housed at night and allowed free movement around an open paddock during the day. A dam in the paddock supported a population of wild waterbirds. From the first outbreak in 1994, a total of 11 isolates of *P. multocida* were obtained for study. The isolates were obtained from the pericardium, lung, and liver of 4 birds, except that for 1 bird, the pericardium isolate was lost before any extensive characterization was performed. In the sec-

From the Institute for Animal Husbandry and Veterinary Science, Beijing Academy of Agricultural and Forestry Science, Beijing, PR China (Zhang), Agency for Food and Fibre Sciences (Fegan, Bowles, Blackall) and Animal and Plant Health Services (Fraser, Duffy, Gordon, Ketterer, Shinwari) Animal Research Institute, Queensland Department of Primary Industries, Yeerongpilly 4105 Australia.

<sup>1</sup>Corresponding Author: P. J. Blackall, Animal Research Institute, Locked Mail Bag No 4, Moorooka 4105, Australia.

ond outbreak in 2002, a total of 11 isolates were obtained from 11 birds. The isolates were obtained from liver (8 birds), heart (2 birds), and thoracic cavity (1 bird).

The isolates were subjected to a phenotypic characterization as follows. The Gram stain reaction of the organisms was determined as described previously.<sup>7</sup> The presence of catalase, oxidase,  $\beta$ -galactosidase, and urease activity and the ability to produce indole were determined as described.<sup>6</sup> The ability to ferment the following carbohydrates was tested using a microplate fermentation method as described previously<sup>1</sup>: L-arabinose, dulcitol, D-glucose, D-lactose, maltose, D-mannitol, D-sorbitol, D-sucrose, D-trehalose, and D-xylose. On completion of the phenotypic characterization, the isolates were assigned to a biovar of *P. multocida* as described previously.<sup>8</sup>

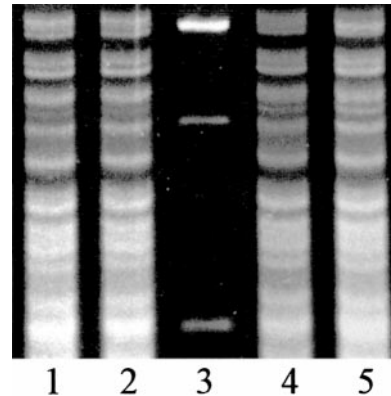
All isolates were serotyped by the Heddlestone somatic serotyping scheme<sup>10</sup> in a gel diffusion test. The antisera used in this serotyping had been produced at this Institute.

All isolates were also examined by the *P. multocida*-specific polymerase chain reaction (PCR) described previously.<sup>12</sup> Restriction endonuclease analysis was performed, using the restriction endonuclease enzyme *Hpa*II, on all the isolates as described previously.<sup>1</sup>

In the 1994 outbreak, disease was seen in adult laying birds (25 weeks old) from only 1 of the 5 houses. Dingoes had attacked this house, which contained 1,200 chickens, 3 nights before the first deaths began. After the first 4 days of the outbreak, 200 chickens had died and 50 were clinically ill. Addition of oxytetracycline to the water on the fourth day of the outbreak resulted in a rapid response. The typical clinical signs seen were increased respiratory rate and yellow diarrhea. Many chickens were prostrate with necks outstretched.

In 2002, another outbreak occurred—mainly affecting a single shed. After 3 days, around 150 chickens had died. Again, oxytetracycline was added to the water, and a rapid response was seen. Two weeks after the episode, the owner was away from the property for 2 days. The disease spread to another 2 sheds during this period, with around 1,500 chickens dying. Oxytetracycline was again added to the water and the deaths ceased. A full course of antibiotic treatment was completed. The typical clinical signs seen in this outbreak were prostrate birds with necks outstretched. There was no evidence of any nasal discharge or swollen wattles or combs.

During the 1994 outbreak, liver with white foci of necrosis was the only gross abnormality, whereas a wider range of lesions was observed during the 2002 outbreak. These included liver necrosis; fibrinous peri-



**Figure 1.** Example of *Hpa*II REA patterns of *P. multocida* isolates. Lanes 1 and 2—2 strains from the 1994 outbreak; lane 3—molecular weight marker; lanes 4 and 5—2 strains from the 2002 outbreak. All 4 isolates show the same REA pattern.

tonitis, pericarditis and perihepatitis; and pneumonia with abscess formation. Histopathological examination of a range of tissues confirmed widespread fibrinopurulent inflammation and necrosis, often with intraleisional bacteria.

In the 1994 outbreak, an organism subsequently shown to be *P. multocida* was recovered in pure culture from the liver, lung, and pericardium of all 4 birds examined. In the 2002 outbreak, 2 submissions of birds were examined. In the first submission, isolates subsequently shown to be *P. multocida* were obtained from the liver and other tissues of all 6 birds examined. In the second submission, which occurred after the commencement of antibiotic treatment, 2 of the 7 birds examined yielded no bacteria on culture. The remaining 5 birds yielded growth typical of *P. multocida* from multiple organs, with only 1 culture per bird being subjected to full characterization.

All 22 isolates examined in detail were gram-negative rods that produced indole, were oxidase and catalase positive,  $\beta$ -galactosidase and urease negative, and fermented glucose, mannitol, sorbitol, sucrose, and xylose but not arabinose, dulcitol, lactose, maltose or trehalose. On the basis of these properties, all the isolates were identified as *P. multocida* subsp *multocida* and were identified as belonging to biovar 3 as defined previously.<sup>8</sup> All isolates were found to be Heddlestone serovar 4. All 22 isolates were positive in the *P. multocida* PCR, and all isolates had the same REA profile (see examples in Fig. 1).

Restriction endonuclease analysis, performed using *Hpa*II, has been shown to be a useful technique for studying the epidemiology of fowl cholera outbreaks in turkeys.<sup>1</sup> Other studies have also reported that *Hpa*II REA patterns are a useful means of differentiating avian isolates of *P. multocida* and identifying clones of *P. multocida*.<sup>3,13,14</sup>

Despite using a range of phenotypic, serotypic, and genotypic tests including REA analysis, no difference between the strains associated with the 1994 and the 2002 outbreaks was detected. This is despite the fact that multiple birds and multiple organs from within some birds were examined. It would appear that a single clone of *P. multocida* caused these 2 outbreaks of fowl cholera.

It has been reported previously that 2 contemporaneous outbreaks of fowl cholera in chickens in Denmark were caused by a single clone (as defined by REA and phenotypic characterization).<sup>3</sup> A recent study<sup>13</sup> has reported that 3 of 7 chicken flocks examined contained healthy birds colonized with *P. multocida*. Each of these 3 flocks was colonized by a single clone of *P. multocida*, as defined by phenotypic testing, with 2 of the farms, one being a brown layer flock with a history of fowl cholera and the other a fowl cholera–vaccinated broiler parent flock, sharing the same phenotypic clone of *P. multocida*. None of the isolates from these chicken flocks<sup>13</sup> were examined by REA.

In fowl cholera outbreaks of turkeys, a single clone of *P. multocida*, as defined by REA or ribotyping (or both), is often associated with outbreaks within a single property.<sup>1,5</sup> The finding of a single clone within a property is not universal as 1 previous study has shown the presence of multiple REA types within 1 of the 3 turkey farms studied.<sup>5</sup>

The only previous molecular study of fowl cholera outbreaks with time involved a Muscovy duck farm.<sup>13</sup> This farm was a multiage farm with a yearly cleanup period in which no bird was present on the property.<sup>13</sup> The property had outbreaks of fowl cholera in 1996 and 1997, but not in 1998.<sup>13</sup> The 1996 and 1997 outbreak strains, as well as the 1998 carrier strains, were all found to have different REA patterns—although within each year group, only a single REA pattern was found.<sup>13</sup> The finding of different REA clones with time may be a result of the yearly clean out period—a period during which no bird was present on the property. In contrast, the farm investigated in the current study did not have a time period in which birds were completely absent from the property during the 8 years separating the outbreaks investigated by the authors.

This study does not provide any evidence on the source of the clone of *P. multocida* associated with these 2 outbreaks. It is possible that there is an outside reservoir that periodically results in entry of *P. multocida*. Alternatively, it is possible that this strain of *P. multocida* is now endemic in birds on this property. The finding that healthy chickens can be carriers<sup>13</sup> suggests that the clone of *P. multocida* may be resident within birds on this property. If the clone is now resident within the birds, then the multiage nature of the

operation makes it most likely that the clinical cases of fowl cholera will continue to occur in the future. Under these circumstances, it would seem that the only control option is to depopulate, thoroughly clean the premise and repopulate with birds free of *P. multocida*. This depopulation–repopulation approach has been recommended by others.<sup>9</sup>

## References

1. Blackall PJ, Pahoff JL, Marks D, et al.: 1995, Characterisation of *Pasteurella multocida* isolates from fowl cholera outbreaks on turkey farms. *Aust Vet J* 72:135–138.
2. Carpenter TE, Snipes KP, Kasten RW, et al.: 1991, Molecular epidemiology of *Pasteurella multocida* in turkeys. *Am J Vet Res* 52:1345–1349.
3. Christensen JP, Dietz HH, Bisgaard M: 1998, Phenotypic and genotypic characters of isolates of *Pasteurella multocida* obtained from back-yard poultry and from two outbreaks of avian cholera in avifauna in Denmark. *Avian Pathol* 27:373–381.
4. Christiansen KH, Carpenter TE, Snipes KP, Hird DW: 1992, Transmission of *Pasteurella multocida* on Californian turkey premises in 1988–89. *Avian Dis* 36:262–271.
5. Christiansen KH, Carpenter TE, Snipes KP, et al.: 1992, Restriction endonuclease analysis of *Pasteurella multocida* isolates from three California turkey premises. *Avian Dis* 36:272–281.
6. Cowan ST: 1974, Cowan and steel's manual for the identification of medical bacteria, 2nd ed. Cambridge University Press, Cambridge, UK.
7. Cruickshank R, Duguid JP, Marmion BP, Swain RHA: 1975, Medical microbiology, 12th ed., vol. 2. Churchill Livingstone, Edinburgh, Scotland.
8. Fegan N, Blackall PJ, Pahoff JL: 1995, Phenotypic characterisation of *Pasteurella multocida* isolates from Australian poultry. *Vet Microbiol* 47:281–286.
9. Glisson JR, Hofacre CL, Christensen JP: 2003, Fowl cholera. *In: Diseases of poultry*, ed. Saif YM, Barnes HJ, Glisson JR, et al., 11th ed., pp. 658–676. Iowa State University Press, Ames, IA.
10. Heddleston KL, Gallagher JE, Rebers PA: 1972, Fowl cholera: gel diffusion precipitin test for serotyping *Pasteurella multocida* from avian species. *Avian Dis* 16:925–936.
11. Kim CJ, Nagaraja KV: 1990, DNA fingerprinting for differentiation of field isolates from reference vaccine strains of *Pasteurella multocida* in turkeys. *Am J Vet Res* 51:207–210.
12. Mifflin JK, Blackall PJ: 2001, Development of a 23S rRNA-based PCR assay for the identification of *Pasteurella multocida*. *Lett Appl Microbiol* 33:216–221.
13. Muhairwa AP, Christensen JP, Bisgaard M: 2000, Investigations on the carrier rate of *P. multocida* in healthy commercial poultry flocks and flocks affected by fowl cholera. *Avian Pathol* 29: 133–142.
14. Muhairwa AP, Christensen JP, Bisgaard M: 2001, Relationships among *Pasteurellaceae* isolated from free ranging chickens and their animal contacts as determined by phenotyping, ribotyping and REA-typing. *Vet Microbiol* 78:119–137.
15. Mutters R, Ihm P, Pohl S, et al.: 1985, Reclassification of the genus *Pasteurella* Trevisan 1887 on the basis of deoxyribonucleic acid homology, with proposals for the new species *Pasteurella dagmatis*, *Pasteurella canis*, *Pasteurella stomatis*, *Pasteurella anatis*, and *Pasteurella langaa*. *Int J Syst Bacteriol* 35: 309–322.
16. Rimler RB, Glisson JR: 1997, Fowl cholera. *In: Diseases of poultry*, ed. Calnek BW, Barnes HJ, Beard CW, et al., 10th ed., pp. 143–159. Iowa State University Press, Ames, IA.